

Stroke treatment during the COVID-19 pandemic

Yuta Tamai^{1,*}, Noritoshi Arai², Makiko Fujitani¹, Seisaku Kanayama¹, Masato Inoue¹, Tetsuo Hara¹

¹Department of Neurosurgery, National Center for Global Health and Medicine, Tokyo, Japan;

²Department of Neurology, National Center for Global Health and Medicine, Tokyo, Japan.

Abstract: Studies have reported that COVID-19 is associated not only with pneumonia but also with cerebrovascular disease. Consequently, medical personnel involved in treating stroke in the emergency medicine setting have been placed in a situation that requires them to provide treatment while always remaining mindful of the possibility of COVID-19. Here, we describe the current state of stroke treatment during the COVID-19 pandemic. Four patients with stroke and concomitant COVID-19 were treated at our facility. We treated 3 patients with cerebral infarction and 1 patient with cerebral venous sinus thrombosis. All 3 patients with cerebral infarction had a poor outcome. This was attributed in part to the poor general condition of the patients due to concomitant COVID-19, as well as to the severity of the major artery occlusion and cerebral infarction. One patient with cerebral venous sinus thrombosis had a good outcome. Anticoagulant therapy was administered at our hospital and resulted in a stable clinical course. Our hospital has worked to establish an examination and treatment system that enables mechanical thrombectomy to be performed even during the COVID-19 pandemic. We devised a protocol showing the steps to be taken from initial treatment to admission to the cerebral angiography room. Our hospital was able to continue accepting requests for emergency admission thanks to the examination and treatment system we established. Up-to-date information should continue to be collected to create examination and treatment systems.

Keywords: COVID-19, stroke, cerebral infarction, cerebral venous sinus thrombosis, mechanical thrombectomy

Since it was first reported in December 2019, COVID-19 has spread throughout the world at an unprecedented speed. Studies have reported that COVID-19 is associated not only with pneumonia but also with cerebrovascular disease. Consequently, medical personnel involved in treating stroke in the emergency medicine setting have been placed in a situation that requires them to provide treatment while always remaining mindful of the possibility of COVID-19.

According to a survey by the Japan Stroke Society (*J*), an analysis of the current state of the emergency medicine system in Japan during the COVID-19 pandemic indicated that, of the 714 primary stroke centers, only 81.7% were accepting requests for emergency admission as they would under normal circumstances in December 2020. This figure was comparable to the situation when a state of emergency was declared (77.8% in May 2020). Eighteen-point-three percent of centers had some type of restriction on care, and 13 centers had to stop accepting requests for emergency admission.

Our hospital has worked to establish an examination and treatment system that enables mechanical thrombectomy to be performed even during the COVID-19 pandemic. After repeated consultations with the medical departments and units involved in stroke

treatment, we devised a protocol showing the steps to be taken from initial treatment to admission to the cerebral angiography room (Figure 1). For emergency outpatient care, a rapid COVID-19 PCR test using a kit to detect nucleic acids of pathogenic microbes (FilmArray[®]) is performed immediately after the patient arrives to reduce the time required for COVID-19 evaluation. Because of the risk of exposure associated with tracheal intubation during treatment, patients for whom endovascular therapy is indicated are intubated in advance, during emergency outpatient care. If the patient definitively tests positive for COVID-19, the number of medical staff involved in the treatment is minimized, and the staff wear personal protective equipment. The steps to be taken from initial treatment to angiography room admission shown in the protocol were simulated using mannequins to establish measures to prevent infection and environmental contamination.

Between January 2020 and December 2021, mechanical thrombectomy was performed 54 times before the COVID-19 pandemic (2018 and 2019) and 40 times afterwards (2020 and 2021). Although our hospital was able to continue accepting requests for emergency admission thanks to the examination and treatment system we established, there was a decrease

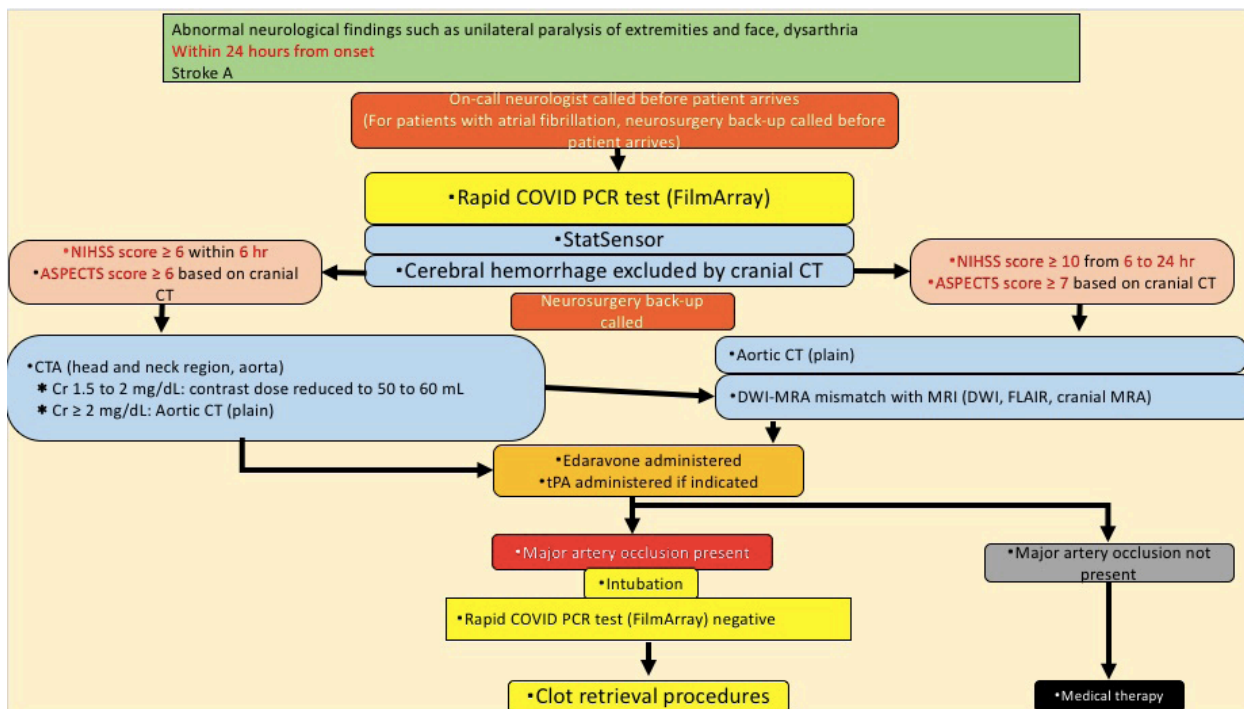


Figure 1. Protocol. This protocol shows the steps to be taken from initial treatment to admission to the cerebral angiography room.

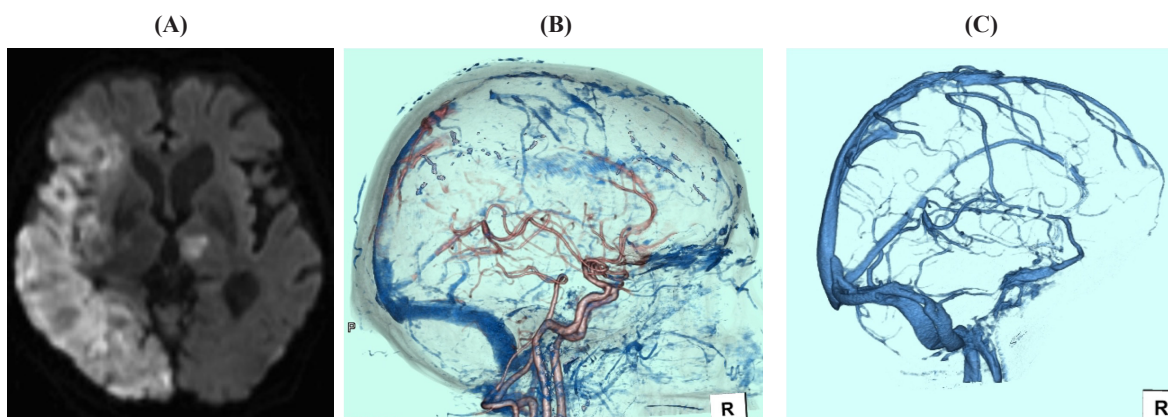


Figure 2. (A) A crania MRI scan revealing acute infarcts from the right frontal lobe to the temporo-occipital lobe and in the left thalamus; **(B)** CTV revealed a deficit from the superior sagittal sinus to the right sigmoid sinus; **(C)** CTV 1 month later revealed alleviation of sinus thrombosis. MRI, magnetic resonance imaging; CTV, computed tomography venography.

in the number of times mechanical thrombectomy was performed. The mean time from hospital arrival to the start of treatment has increased from 93.2 minutes before the COVID-19 pandemic (2018 and 2019) to 105.6 minutes since its start (2020 and 2021). Moreover, the time from onset to hospital arrival has increased from 141 minutes to 150.4 minutes. Studies of stroke treatment during the COVID-19 pandemic have indicated that fewer patients were hospitalized for stroke and fewer clot removal procedures were performed during periods that COVID-19 increased. Changes in examination and treatment systems (the need to limit acceptance of non-COVID-19 patients as treatment of COVID-19 patients has increased) and in patient behavior (e.g., patients with

mild disease refraining from receiving treatment) have been discussed as possible causes (2). Moreover, the time from hospital arrival to the start of treatment has increased. This was attributed to additional steps taken before treatment, such as PCR testing and intubation.

We have not seen any patients with concomitant COVID-19 for whom mechanical thrombectomy was indicated, but four patients with stroke and concomitant COVID-19 were treated at our facility. Three of those patients had cerebral infarction. One was a 78-year-old male, one was a 55-year-old female, and the remaining one was an 80-year-old male who had major artery occlusion (Figure 2A). All 3 patients were treated conservatively but had a poor outcome. This was

attributed in part to the poor general condition of the patients due to concomitant COVID-19 as well as to the severity of major artery occlusion and cerebral infarction. We also treated one patient with cerebral venous sinus thrombosis, a 46-year-old man. Computed tomography venography (CTV) revealed a deficit from the superior sagittal sinus to the right sigmoid sinus, and the patient was diagnosed with cerebral venous sinus thrombosis (Figure 2B). Blood tests revealed an elevated D-dimer level (30.9). Anticoagulant therapy with heparin and warfarin was administered. The patient's clinical course was good, and follow-up CTV 1 month later revealed alleviation of sinus thrombosis (Figure 2C).

According to a review that summarized 26 studies of the relationship between COVID-19 and stroke from the first study to August 2020, the incidence of cerebral infarction in inpatients positive for COVID-19 was 1.5% (0.1% to 6.9%) (3). The fact that the incidence differed depending on the study suggested that imaging studies could not be adequately performed to prevent the spread of infection and that strokes may have been overlooked in patients on mechanical ventilation (3). Most of the strokes were cerebral infarctions, which accounted for more than 70% to 80% of the total. This was followed, in descending order, by cerebral hemorrhage (approximately 10% to 15%), cerebral sinus thrombosis (approximately 0.5% to 4%), and subarachnoid hemorrhage (4). Examination by type of cerebral infarction indicated that cerebral infarction with no identifiable cause (cryptogenic cerebral infarction) was the most common. This was followed, in descending order, by cardiogenic brain embolism, atherothrombotic cerebral infarction, and lacunar infarction (4). Multiple vascular areas were often affected, and many patients tended to have a concomitant intracerebral hemorrhage or major artery occlusion. Compared to non-stroke patients, those with concomitant stroke were older and more often had hypertension, diabetes mellitus, coronary artery disease, and severe COVID-19 (4).

Cerebral venous sinus thrombosis was reported in 39 patients in March 2021. The time of onset was most often within 8 days of diagnosis of COVID-19, which was the case in 67% of the patients, and the most common symptoms included headaches, convulsions,

and stroke-like symptoms. As is the case for normal cerebral venous sinus thrombosis, anticoagulant therapy was the treatment most commonly administered (5). Anticoagulant therapy was also administered at our hospital and resulted in a stable clinical course.

The current study has described the current state of stroke treatment during the COVID-19 pandemic. Up-to-date information should continue to be collected to create examination and treatment systems.

Funding: None.

Conflict of Interest: The authors have no conflicts of interest to disclose.

References

1. The Japan Stroke Society. Survey on the impact of COVID-19 on stroke emergency care - Statement based on the December 2020 Situation. https://www.jsts.gr.jp/news/pdf/20210105_covid.pdf (accessed march 23, 2022). (in Japanese)
2. Nogueira RG, Abdalrhader M, Qureshi MM, *et al.* Global impact of COVID-19 on stroke care. *Int J Stroke*. 2021; 16:573-584.
3. Sagris D, Papanikolaou A, Kvernland A, Korompoki E, Frontera JA, Troxel AB, Gavriatopoulou M, Milionis H, Lip GYH, Michel P, Yaghi S, Ntaios G. COVID-19 and ischemic stroke. *Eur J Neurol*. 2022; 28:3826-3836.
4. Kawano H. COVID-19 and stroke. *Jpn J Thrombosis Hemostasis* 2021; 32:723-725.
5. Ghosh R, Roy D, Mandal A, Pal SK, Chandra Swaika B, Naga D, Pandit A, Ray BK, Benito-León J. Cerebral venous thrombosis in COVID-19. *Diabetes Metab Syndr*. 2021; 15:1039-1045.

Received March 23, 2022; Revised September 10, 2022; Accepted September 21, 2022.

Released online in J-STAGE as advance publication September 30, 2022.

**Address correspondence to:*

Yuta Tamai, Department of Neurosurgery, National Center for Global Health and Medicine, 1-21-1 Toyama, Shinjuku-ku, Tokyo 162-8655, Japan.

E-mail: ytamai@hosp.ncgm.go.jp