

# Prevention of cuff injury of the intubation tube by blunt window opening in tracheostomy

Kenshiro Taniguchi\*, Katsuhiko Tsutsumiuchi, Yukiko Sagara, Niro Tayama

Department of Otolaryngology, National Center for Global Health and Medicine, Tokyo, Japan.

**Abstract:** One of the intraoperative complications of tracheostomy under general anesthesia is cuff injury of the intubation tube. In the present study, we investigated whether a blunt tracheal opening is a useful method to avoid cuff injury. A retrospective cohort study was conducted to examine patients who underwent tracheostomy under general anesthesia at a single institution from January 1, 2017 to July 31, 2021. Electrocautery was used to thin the connective tissue between the tracheal rings, and bluntly open the trachea with mosquito forceps or similar instruments. Primary outcomes included cuff injury rate, number of surgeons involved, and career as otolaryngologist at the time of surgery. The secondary outcome was perioperative complications. Of the 64 cases, 3 had cuff injuries. 2 of the 3 had cuff injuries during the creation of an anteriorly based flap. 16 surgeons were involved ranging from the first to sixth year as an otolaryngologist, with the third year of otolaryngologist being the most common. The median physician year for instructors was 18 years. The most common postoperative complication was granulation in 9 cases. There were no cases of incorrect cannula insertion or difficulty in cannula insertion. A blunt tracheal opening was considered useful as a method to prevent cuff injury.

**Keywords:** tracheostomy, cuff injury, blunt window opening, aerosol's generation

## Introduction

Tracheostomy is one of the oldest and most commonly performed procedures in respiratory critically sick patients. Tracheostomy is the process of creating an opening in the anterior wall of the trachea. Surgical tracheostomy refers to placement of a tracheostomy cannula under direct vision after dissection of pretracheal tissues and incision of the tracheal wall. When opening the trachea, incisions with scalpels are generally known. Premature intubation tube cuff injury, which can occasionally occur during tracheostomy, can result in failure of ventilation and poor visualization (1).

In this study, we describe a simple change from the method of cutting the trachea with a scalpel to the method of bluntly opening the trachea in order to reduce the probability of cuff injury and thus prevent ventilation difficulties and aerosol generation.

We also examined whether this technique can be performed by anyone as a standard procedure. Furthermore, by examining the perioperative complications, we examined whether this is a safe method of tracheostomy. We will demonstrate the method and its effectiveness so that the surgeon who reads this paper can immediately put it into practice.

## Patients and definitions

The present, retrospective cohort study was performed at National Center for Global Health and Medicine from January 2017 to August 2021 and enrolled patients who underwent tracheostomy in the Department of Otolaryngology under general anesthesia. Tracheostomy cases associated with other surgeries, such as facial bone fracture surgery, were excluded. Cases that were not anesthetized by an anesthesiologist were excluded. Tracheostomy is only surgical tracheostomy and does not include percutaneous dilatational tracheostomy. All patients underwent tracheostomy because of the prospect of long-term intubation. The tracheostomy procedure performed in our department consists of tracheal fenestration, which is suturing the tracheal window with surrounding skin. This is to prevent accidental cannula insertion to the outside of the trachea.

The study protocol was approved by the ethics committee at National Center for Global Health and Medicine (approval no. NCGM-S-004370-00).

## Study design

The patients' demographic and baseline data were

collected from the electronic medical records at National Center for Global Health and Medicine. Age at surgery, gender, height, weight, BMI, and co-morbidities were collected. The use of antithrombotic and anticoagulant drugs was examined. Outcome of hospitalization and duration of hospitalization were also examined. Perioperative records were investigated for operative time, anesthesia time, blood loss, cuff injury, tube movement before tracheostomy, cuff position during tracheostomy, and disturbance of EtCo<sub>2</sub>. The number of surgeons involved in our tracheostomy and the number of years as an otolaryngologist were also examined. Postoperative complications included postoperative bleeding, postoperative infection, tube occlusion, tracheal granulation, incorrect insertion of the cannula, and difficulty in cannula exchange.

The primary outcome was the presence of cuff damage, referring to surgical and anesthesia records and changes in EtCo<sub>2</sub>. The number of cases in which the cuff was directly underneath the tracheostomy window was also examined. We also examined whether the intubation tube was moved caudally to shift the position of the cuff caudally before opening the trachea. In addition, the number and year of the surgeons and instructors involved in tracheostomy in our hospital were examined to determine its validity as a standard procedure that does not require special skills that only expert surgeons can perform. The goal is to show that this surgical procedure is effective in preventing cuff damage and does not require special skills.

As secondary outcomes, we evaluated the safety of tracheostomy performed in our department by assessing postoperative complications.

### Surgical tracheostomy techniques

There is no special procedure until the anterior tracheal wall is exposed. The tracheotomy is usually carried out in the 2nd or 3rd tracheal rings. The power of the electrocautery is set at 25 watts. When cauterizing the peritracheal area, the oxygen concentration is kept close to room air to ensure that no high concentrations of oxygen are delivered.

Electrocautery was used to gradually thin the connective tissue between the tracheal rings (Figure 1A). The tracheal mucosa is cauterized until only a thin layer is left (Figure 1B), and bluntly open the trachea with mosquito forceps or similar instruments (Figure 1C). If the cuff is visible (Figure 1D), the intubation tube is pushed caudally by the anesthesiologist. An anteriorly based flap is then created with surgical scissors and the skin and flap are sutured. In our hospital, for patients who are expected to be intubated for a long period of time, the tracheal window and skin are sutured together (Figure 1E). Even when long-term cannula placement is not anticipated, the four corners of the tracheal foramen are sutured to the surrounding skin to prevent stenosis and facilitate cannula replacement. As the cuff is not injured, the suturing procedure can be fully performed.

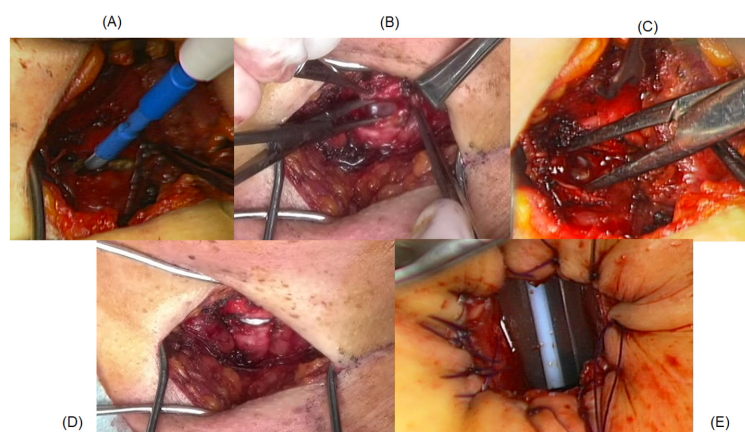
### Baseline characteristics and primary outcome

Sixty-four patients met the inclusion criteria. The patients' demographic and perioperative baseline data are shown in Table 1. Median operation and anesthesia time were 44 and 84 minutes. Median amount of bleeding was low.

Primary outcome is also shown in Table 1. The cuff was injured in three (4.7%) cases. Disturbance of EtCo<sub>2</sub> was also observed in the same cases. In two of the three cases, the cuff was injured when creating the anteriorly based flap, not when opening the trachea. When the trachea was opened, the cuff was found directly below the opening in 28 (43.8%) cases. In five cases, the intubation tube was moved caudally before opening the trachea. However, in one of the five cases, the cuff was found just below the tracheal opening. 16 otolaryngologists were performing the procedure. The median experience of the surgeon as an otolaryngologist was 3 years. The median physician year for instructors was 18 years.

### Preventing cuff technique

A well-known method of preventing cuff injury is to move the cuff caudally before opening the trachea, which



**Figure 1. Surgical technique.** (A) electrocautery was used to gradually thin the connective tissue between the tracheal rings, (B) the tracheal mucosa is cauterized until only a thin layer is left, and (C) bluntly opening the trachea with mosquito forceps or similar instruments. (D) If the cuff is visible, the intubation tube is pushed caudally by the anesthesiologist. (E) For patients who are expected to be intubated for a long period of time, the tracheal window and skin are sutured together.

**Table 1. The patients' demographic and perioperative baseline data and primary outcome**

<i>The patients' demographic and perioperative baseline data</i>		
The number of patients	64	
median Age	70 (60–77)	
Male	44 (69%)	
Female	20(31%)	
median Height(cm)	163	
median Weight(kg)	59.3	
BMI(median)	22.8	
median Operation time(min)	44 (39–54)	
median Anesthesia time(min)	84 (72–93)	
median Amount of Bleeding	few	
<i>Primary Outcome</i>		
① Cases of the cuff injury		
Cuff injury	3/64	4.68(%)
Changes in EtCo2	3/64	
② Positioning of the cuff		
Cuff directly under the tracheal opening	28*/64	43.8(%)
Cuff located cephalad to the tracheal opening	1/64	
③ Moving of the cuff		
Caudal move of intubation tube before tracheostomy	5/64	
④ Surgeons included		
Total number of surgeon	16	
Median years of practicing otolaryngologist	3	
Median number of years of instructing physician	18	

The cuff was injured in three (4.7%) cases. In two of the three cases, the cuff was injured when creating the anteriorly based flap, not when opening the trachea. The cuff was found directly under the opening in 28 (43.8%) cases. Sixteen otolaryngologists performed the procedure and the median experience of the surgeons as an otolaryngologist was 3 years. \*In one case, the cuff was found just below the window opening even though the intubation tube was moved caudally.

was reported to have prevented cuff injury in 123 of 129 cases (2). However, there are cases in which the tube was not moved caudally properly. In our study, there was one case in which the cuff was found directly under the tracheal opening even after the tube was actually moved, and one case in which the cuff was located cephalad to the opening when the trachea was opened. When opening the trachea, incisions with scalpels are generally known, but a blunt opening is rarely seen. With this technique, theoretically, the possibility of cuff injury can be reduced to almost zero because the trachea is opened bluntly. In two of the three cases where the cuff was injured, the injury occurred when the flap was made, not when the trachea was opened. In this study, there were 28 cases (43.8%) in which the cuff was directly under the tracheal opening, suggesting that there is a high risk of cuff injury if no precautions are taken. If the cuff is directly under the tracheal opening, there is always a possibility of injuring the cuff as long as the trachea is opened sharply with a scalpel, no matter how carefully it is done.

### Establish the standardization of surgery

Tracheostomy is a basic surgical technique for the airway, and it is likely that many young otolaryngologists will be the primary surgeons. In particular, tracheostomies for

non-urgent, intubated patients under general anesthesia are likely to be performed by younger surgeons. If the cuff is injured during tracheal opening, ventilatory management becomes unstable (1), and it is difficult to perform the settled surgery. It is very important to ensure a settled operation in order to reduce patient burden and to allow young surgeons to complete the operation. A total of 16 otolaryngologists with less than 6 years of experience in otolaryngology were involved in the tracheostomy at our hospital. With standard surgical skills, this procedure is considered practicable.

### Secondary outcome

Postoperative complications, including minor ones, were observed in 19 cases. The most common complication was granulation in 9 cases, but none of them resulted in airway stenosis, only small granulation around the trachea that did not affect the airway or cannula exchange. Granulation is considered to be generated by stimulation of cannula insertion, and it is assumed that suturing the tracheal opening to the surrounding skin prevented the formation of a large granulation. Accidental decannulation was observed in 6 patients, but there was no stenosis of the tracheal canal in all cases, so there was no case of difficulty in cannula insertion. Difficulty in reinserting the cannula after decannulation would be a serious problem, but the stable tracheal opening led to the avoidance of cannula insertion difficulties. In one case, minor bleeding from the airway was observed 2 months after surgery, but no specific cause could be identified. Other cases were 2 cases of recurrent aspiration, 1 case of infection, 1 case of subcutaneous emphysema, and 1 case of tube obstruction.

Antithrombotic and anticoagulant drugs were used in 14 cases. However, none of them had a problem with perioperative bleeding. The process of thinning the trachea with electrocautery is also advantageous in that it reduces bleeding when the trachea is opened.

As for the outcome of hospitalization, 28 patients were discharged dead, 31 patients were transferred, and 5 patients were discharged home.

### Complications of tracheostomy

Complications of tracheostomy can be divided into intraoperative, early, and late. Intraoperative complications include hemorrhage; pneumomediastinum, pneumothorax, and recurrent laryngeal nerve injury; and cuff rupture of the intubation tube. Early complications include hemorrhage, tracheitis, mucous plugging, accidental decannulation, subcutaneous emphysema, and swallowing problems (3). Late complications can include tracheal stenosis from excessive granulation tissue, tracheomalacia, tracheoesophageal fistula, tracheoinnominate artery fistula, and recurrent aspiration (4).

Tracheostomies are generally considered safe

procedures, but can result in untoward complications. In a recent survey of American Academy of Otolaryngology–Head and Neck Surgery members, it was calculated that 55% of otolaryngologists cared for at least 1 patient who underwent tracheostomy that resulted in a catastrophic complication (5). In particular, the overall incidence of tracheostomy complications has been suggested to be 3.2% (6). In proposing a new surgical method in the present study, the trachea was opened bluntly, and there seemed to be no significant complications compared to the common complications of tracheostomy.

### Tracheal fenestration

The development of granulation causes difficulty in replacing the tracheostomy tube, and may delay decannulation and interfere with the function of the tracheostomy. Obstruction related to granulation tissue has been cited as the cause of death in several patients (7). Using a surgical technique that mobilizes cervical skin flaps to create a circumferential mucocutaneous junction at the window has been suggested as a method to decrease development of granulation tissue. This technique has been suggested for patients who are thought to need a "permanent" or long-term tracheostomy (7,8).

In order to facilitate cannula management without the need for an otolaryngologist who is experienced in airway management, we perform tracheotomy with tracheal fenestration, in which the tracheal window and skin are fixed in a circumferential fashion.

In order to perform tracheal fenestration, it is necessary to open the trachea without injuring the cuff and then allow time for suturing the tracheal window to the skin.

### Prevention of Aerosol generation

Many societies have recommended that Aerosol-Generating Procedures be avoided as much as possible and tracheostomy is said to be an Aerosol-Generating Procedure (9). In general, tracheostomy is associated with an increased production of aerosols and a higher risk of viral transmission to healthcare personnel (10). Injury of the cuff during tracheostomy increases the risk of infection from some virus from the patient to the surgeon.

Avoidance of Aerosol-Generating Procedures will continue to be important not only for new coronaviruses but also for general infection control. Therefore, it is strongly recommended that this technique, which bluntly opens the trachea to prevent cuff tube injury, be used as

the standard procedure to prevent aerosol generation.

In conclusion, compared to sharp opening, blunt opening of the trachea is a very useful method in establishing a safe tracheostomy, because it requires no special skills and prevents damage to the cuff of the intubation tube.

*Funding:* None.

*Conflict of Interest:* The authors have no conflicts of interest to disclose.

### References

- Gillies M, Smith J, Langrish C. Positioning the tracheal tube during percutaneous tracheostomy: Another use for videolaryngoscopy. *Br J Anaesth.* 2008; 101:129.
- Sood A, Taheri MR, Joshi AS. Preventing cuff rupture during tracheostomy: Importance of endotracheal tube positioning. *Ann Otol Rhinol Laryngol.* 2014; 123:654-657.
- Halum SL, Ting JY, Plowman EK, *et al.* A multi-institutional analysis of tracheotomy complications. *Laryngoscope.* 2012; 122:38-45.
- Epstein SK. Late complications of tracheostomy. *Respir Care.* 2005; 50:542-549.
- Das P, Zhu H, Shah RK, Roberson DW, Berry J, Skinner ML. Tracheotomy-related catastrophic events: Results of a national survey. *Laryngoscope.* 2012; 122:30-37.
- Shah RK, Lander L, Berry JG, Nussenbaum B, Merati A, Roberson DW. Tracheotomy outcomes and complications: A national perspective. *Laryngoscope.* 2012; 122:25-29.
- Yaremchuk K. Regular tracheostomy tube changes to prevent formation of granulation tissue. *Laryngoscope.* 2003; 113:1-10.
- Eliachar I, Oringer SF. Performance and management of long-term tracheostomy. *Operative Techniques in Otolaryngology-Head and Neck Surgery.* 1990; 1:56-63.
- Klompas M, Baker M, Rhee C. What is an aerosol-generating procedure? *JAMA Surg.* 2021; 156:113-114.
- Tran K, Cimon K, Severn M, Pessoa-Silva CL, Conly J. Aerosol generating procedures and risk of transmission of acute respiratory infections to healthcare workers: A systematic review. *PloS one.* 2012; 7:e35797.

----

Received January 18, 2023; Revised September 15, 2023; Accepted October 30, 2023.

Released online in J-STAGE as advance publication November 21, 2023.

*\*Address correspondence to:*

Kenshiro Taniguchi, Department of Otolaryngology, National Center for Global Health and Medicine, 1-21-1 Toyama, Shinjuku, Tokyo 162-8655, Japan.  
E-mail: ktani2020office@gmail.com